

# Swallow-related cerebral cortical activity maps are not specific to deglutition

MARK KERN, RASMUS BIRN, SAFWAN JARADEH, ANDREI JESMANOWICZ,  
ROBERT COX, JAMES HYDE, AND REZA SHAKER

*Medical College of Wisconsin Dysphagia Institute, Departments of Medicine and Radiology and  
the Biophysics Research Institute, The Medical College of Wisconsin, Milwaukee, Wisconsin 53226*

Received 22 June 2000; accepted in final form 11 October 2000

**Kern, Mark, Rasmus Birn, Safwan Jaradeh, Andrei Jesmanowicz, Robert Cox, James Hyde, and Reza Shaker.** Swallow-related cerebral cortical activity maps are not specific to deglutition. *Am J Physiol Gastrointest Liver Physiol* 280: G531–G538, 2001.—Cortical representation of swallow-related motor tasks has not been systematically investigated. In this study, we elucidated and compared these cortical representations to those of volitional swallow using block-trial and single-trial methods. Fourteen volunteers were studied by functional magnetic resonance imaging. Cortical activation during both swallowing and swallow-related motor tasks that can be performed independent of swallowing, such as jaw clenching, lip pursing, and tongue rolling, was found in four general areas: the anterior cingulate, motor/premotor cortex, insula, and occipital/parietal region corresponding to Brodmann's areas 7, 19, and 31. Regions of activity, volume of activated voxels, and increases in signal intensity were found to be similar between volitional swallow and swallow-related motor tasks. These findings, using both block-trial and single-trial techniques, suggest that cerebral cortical regions activated during swallowing may not be specific to deglutitive function.

brain and swallowing; brain function and deglutition

---

CENTRAL CONTROL OF VOLITIONAL swallowing involves both the brain stem and the cerebral cortex. Although the current understanding of central control of swallowing is rapidly evolving, a growing body of clinical as well as experimental evidence indicates an integral role for cerebral cortical mechanisms in both initiation and regulation of volitional swallow. Direct investigation of the human cerebral cortical areas involved in swallowing, however, has only recently become possible with the advent of noninvasive techniques, such as positron emission tomography and functional magnetic resonance imaging (fMRI) (5, 6, 16–20).

Cortical representation of swallowing is suggested to be multifocal (5, 6, 16–20) and bilateral, with handedness-independent hemispheric dominance (16, 18, 19). Various areas of the cerebral cortex, such as the sensory motor cortex, cingulate gyrus, and insula, have been found to become activated during volitional swal-

lowing (17, 19, 20). These areas represent the summation of the activated cortical regions involved in swallowing. The cortical representation of the swallow-related motor tasks and their contribution to the sum of activated cortical regions during swallowing has not been systematically investigated. It is also not clear whether cortical representation of these swallow-related tasks is similar to the findings reported for volitional swallow with regard to cortical regions of activity and laterality.

The aim of the present study, therefore, was to elucidate the cortical representation of three swallow-related motor events, namely lip pursing, tongue rolling, and jaw clenching, that are also routinely performed by humans for nondegutitive purposes and to compare these cortical representations to those of volitional swallowing.

## METHODS

fMRI is a recently developed technique for functional study of the cerebral cortex of the human brain. By measuring the local changes in oxyhemoglobin concentration in regions of increased neuronal activity, fMRI has been shown to accurately detect cortical activity during motor and sensory stimulation (3, 4, 7, 11, 12, 14, 24, 30, 34).

In addition to the use of magnetic resonance (MR) techniques to create high-resolution anatomic images, MR techniques are also used to detect changes in magnetic properties of human tissue. The focus of the present study is detection of functional cerebral activity due to local changes in deoxyhemoglobin concentration. Blood oxygenation level-dependent contrast is based on the fact that as blood is deoxygenated the diamagnetic oxyhemoglobin changes to paramagnetic deoxyhemoglobin (3, 4). This change in magnetic susceptibility alters the local distribution of the field within a single pixel and results in changes in signal intensity, greater oxygen concentration being associated with a brighter pixel. The pixel brightness is scaled and stored as a numeric value ranging from 0 (a black pixel) to a maximum value dependent on the applied magnetic field strength. Thus a time course of gradient echo MRI images shows subtle changes in contrast in regions of altered oxygenation rate. The anatomic location of the contrasted region is associated with the control or sensation of any physiological stimuli provided during the acquisition of MR images.

---

Address for reprint requests and other correspondence: R. Shaker, Division of Gastroenterology and Hepatology, Froedtert Memorial Lutheran Hospital, 9200 W. Wisconsin Ave., Milwaukee, WI 53226 (E-mail: rshaker@mcw.edu).

---

The costs of publication of this article were defrayed in part by the payment of page charges. The article must therefore be hereby marked "advertisement" in accordance with 18 U.S.C. Section 1734 solely to indicate this fact.

Stereotaxic transformations of the MR brain images for intra- and intersubject comparisons are performed using the Talairach-Tournoux coordinate system (30). In this system, a brain is scaled by three axes. The *y*-axis (anterior to posterior) runs through an imaginary line spanning the superior edge of the anterior commissure and the inferior edge of the posterior commissure. The *z*-axis (superior to inferior) is also in the midsagittal plane, perpendicular to the *y*-axis and passing through the posterior margin of the anterior commissure. The *x*-axis (right to left) is perpendicular to the *y*- and *z*-axes and passes through their intersection. Brain dimensions are then scaled to the size of the extremes of the cerebellum in the direction of the defined axes.

A nonbiased method of detecting those regions that exhibited changes in oxy/deoxyhemoglobin concentration is achieved by applying a cross-correlation technique that compares an idealized paradigm and an actual MRI-generated time course. This correlation technique has been successful in detecting regions of cortical activation in other fMRI studies of motor task activation (3), photic activation of the visual cortex (14), auditory response (7), memory (12), psychotropic drug effects (34), and esophageal sensation (23). From an analytical point of view, this method of data analysis has two components: 1) to set a reasonable threshold for the probability of detecting activity similar to the stimulation paradigm (that is, for what value of the correlation coefficient will we accept a time series as being significantly correlated with the stimulus paradigm?) and 2) to choose the appropriate temporal shift for the idealized reference waveform. The temporal shift represents the interval between the onset of stimulation and the onset of detectable fMRI changes induced by the stimuli.

We systematically calculated correlation coefficients for every pixel in each MRI image time series. A probability threshold was set below which a pixel is excluded from consideration as a region of cortical activation. Although there is considerable variability among researchers in the probability level deemed acceptable for inclusion or exclusion, a range of 0.4–0.7 covers the published spectrum (3, 7, 12, 14, 34). We chose to use 0.7 as a conservative criterion for correlation threshold. Using software developed and validated (11) by the Biophysics Research Institute at the Medical College of Wisconsin running on a Silicon Graphics Indigo II workstation, we were able to calculate the correlation coefficients for idealized waveforms and fMRI time series.

Once the activated regions were established using the thresholding technique described above, a color map was produced indicating the anatomic positions of the pixels that exceed the correlation threshold. These color maps were overlain on the anatomic MR images to give an indication of functional anatomic location.

A common method of eliciting a cerebral cortical fMRI response for correlation analysis is the block-trial method. This stimulus-delivery technique is characterized by alternating intervals of repeated stimulus and periods of rest. In a block-trial swallow study, for example, 15 s of repeated swallowing would be followed by 15 s of no swallowing. These alternating intervals of swallowing and rest are repeated several times during a MR scanning sequence. Although this technique is designed to increase cortical blood flow to activation regions by the additive effect of multiple stimuli, the performance of multiple stimuli increases the probability of detecting motion-induced magnetic field changes in cortical regions of interest. These motion-induced artifactual field changes are unrelated to the cortical blood flow changes associated with the stimuli but may appear in cortical re-

gions wherein stimulus-induced changes in cortical hemodynamics also exist (5, 6).

To lessen the artifactual effects produced by the block-trial swallow study method, a single-trial technique has been developed (5, 6). In this approach, fMRI images are gathered immediately after a single swallow (or swallow-related event) using the inherent motion MRI signal artifact as a triggering event to reference and average fMRI signal changes induced by repetitive tasks. Since fMRI signal changes related to cortical blood oxygenation rate for a single event are on the order of 0.5–3% (3–6) above baseline signal values, many single trials are averaged to enhance the effect of recurrent signal changes due to deglutition and to reduce the effect of artifactual signal changes due to task-related motion.

Using the above-described block-trial and single-trial blood oxygenation level-dependent techniques, we studied the cerebral cortical response to the swallow-related motor tasks of lip pursing, tongue rolling, and jaw clenching and the cerebral cortical response to volitional swallowing. Our specific aims were to 1) characterize and compare the regions of cortical activity associated with the tested swallow-related motor tasks with the cortical regions associated with volitional swallowing and 2) evaluate the efficacy of the single-trial technique in reducing the motion artifact inherent in block-trial swallow-related fMRI studies.

### Subjects

A total of 15 studies were performed in 14 healthy volunteers (3 female, 11 male, age range 21–42 yr) with no past or current gastrointestinal symptoms. The three different protocols are described below. All but one subject was right handed. Studies were approved by the Human Research Review Committee of the Medical College of Wisconsin, and all subjects gave written informed consent before their studies.

### MRI Scanning

Echo planar and anatomic MR images were acquired in the sagittal and axial planes for localized and whole brain images. MRI was performed using contiguous sagittal or axial slices. Scanning was done on a 1.5-T General Electric Signa Scanner in five subjects and on a 3-T Bruker Scanner in 10 subjects. Each scanner was equipped with a custom-made 3-axis head coil designed for rapid gradient field switching and a shielded, transmit/receive “birdcage” radio frequency coil to acquire a time course of echo planar images over the desired cortical region and slice specifications (3, 4, 7, 14, 34). Studies were conducted in three groups.

*Study group 1: comparison of single and block trials of swallow-related motor tasks.* Five subjects were studied to compare the block-trial and single-trial techniques for the swallow-related motor tasks of tongue rolling, lip pursing, and jaw clenching. During six 150-s scans of 10 axial, 0.5-cm-thick slices traversing the cortex sampled at 1 Hz, two kinds of trial were performed, one trial being alternating intervals of no activity and repetitive activity (block trial) and the other trial being a single activity every 15 s. In the block trials, there were four intervals of repeated motor tasks. In the single trials, there were eight single motor tasks with a 15-s interval of rest in between each single task.

*Study group 2: comparison of single and block trials of volitional swallowing.* Five subjects were studied to compare the block-trial and single-trial techniques for swallowing. During four 150-s scans of 10, 0.5-cm-thick slices traversing the cortex sampled at 1 Hz, two kinds of trial were performed, one trial being alternating intervals of no activity

and repetitive swallowing (block trial) and the other trial being a single swallow every 15 s. In the block trials, there were four intervals of repeated swallowing. In the single trials, there were eight single swallows with a 15-s interval of no swallowing in between each single swallow.

*Study group 3: comparison of cerebral cortical activity regions of volitional swallowing and swallow-related tasks.* Five subjects were studied using the following block-trial protocol. Five 110-s scans of nine sagittal 1.5-cm-thick slices were sampled at 1 Hz, alternating 15-s intervals of no activity and activity. Subjects were signaled to begin and end an activity by a single, gentle tap on the leg. The type of activity (tongue rolling, lip pursing, jaw clenching, and swallowing) within each 110-s scan was not varied; however, the sequence of scan types was randomly varied from one individual to the next.

#### Measured Temporal Parameters

Figure 1 shows a schematic representation of the fMRI signal-timing parameters evaluated in all of our study protocols. The estimate for activation latency was determined by the value for which the idealized square wave was shifted in time to yield the greatest number of correlated pixels that exceeded the threshold probability described above. All other temporal characteristic values were determined from visual inspection of each fMRI time series that exceeded the threshold procedure.

#### Cluster Analysis of Cerebral Cortical fMRI Activation Images

To facilitate calculation of regional activity volumes and average signal increase associated with swallowing and swallow-related motor tasks, we applied the further requirement that regions shown on the cortical activity maps must be arranged in clusters of three or more contiguous voxels to be mapped as significantly correlated regions. The cluster criteria were applied to all voxels that passed our correlation standard to form cluster maps that were used for comparison within and between subjects.

## RESULTS

Both block-trial and single-trial paradigm-driven tasks resulted in a significant increase in fMRI signal intensity in several cortical regions during both voli-

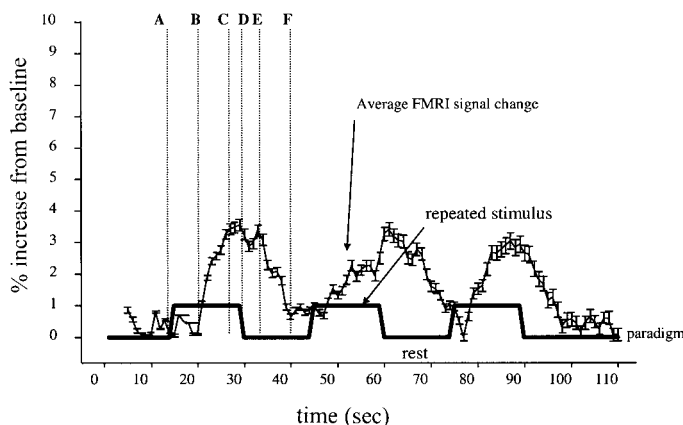


Fig. 1. Schematic representation of the cerebral cortical functional magnetic resonance imaging (fMRI) temporal characteristics measured in our study. A to B, activation latency; B to C activation to peak; D to E, deactivation latency; E to F, deactivation to baseline.

tional swallowing and swallow-related motor tasks. Although the block-trial and single-trial techniques differed in terms of the specific coordinates of cortical activity represented by the pixels correlated to the motor activity paradigms, the general anatomic regions of cortical activity were similar for the two techniques for each task.

#### Group 1 Studies: Comparison of Cerebral Cortical Activity During Swallow-Related Motor Tasks Using Block-Trial and Single-Trial Techniques

Effects associated with motion artifact as reported previously (5, 6) limited accurate interpretation of cortical activation regions elicited during block-trial stimulation in individual studies. The motion-related artifact was primarily manifested on the perimeter of the brain image outside of the cortex. These artifactual areas varied from one individual to the other. Taking into analysis only the areas that were common among the study subjects eliminated the artifactual signals in individual subjects and produced an activity map similar to that of the single-trial technique.

The single-trial averaging technique virtually eliminated motion-related artifacts. The regions of activation associated with the swallow-related motor tasks are shown in Table 1. Two-way ANOVA testing variability due to regions of cortical activity and type of motor task showed that there were no significant differences in any of the measured magnetic signal-timing parameters when comparing the block-trial to the single-trial technique. The composite, average block-trial cortical activity maps were similar to the average activity maps for the single-trial technique.

#### Group 2: Comparison of Cerebral Cortical Activity During Volitional Swallowing Using Block-Trial and Single-Trial Techniques

Although the exact Talairach coordinates of each significantly correlated voxel were not the same in the average activity maps, the general cortical regions of activity were similar (Table 2). There were no significant differences in any of the measured fMRI signal-timing parameters when comparing the block-trial with the single-trial technique.

#### Group 3: Cerebral Cortical Activity During Swallow-Related Motor Tasks and Volitional Swallowing

Regions of cortical activity were similar for all of the swallow-related motor tasks (Table 3). The timing characteristics of the fMRI signal waveforms did not differ significantly among the swallow-related motor tasks. Volitional swallowing showed many shared cortical regions compared with cortical regions associated with the swallow-related motor tasks (Table 3).

The results of the cluster analyses are depicted in Fig. 2. In the *group 1* data, the cluster analysis showed the single-trial technique to be capable of detecting magnetic signal changes in cortical regions otherwise concealed by motion artifact, especially for the jaw-clenching task. Also shown by the cluster analysis was

Table 1. *Regions of activation in block- and single-trial studies of lip pursing, jaw clenching, and tongue rolling*

Subject	Block Trial		
	Lip pursing	Jaw clenching	Tongue rolling
1	6, 7, 19, 23, 30, 32, insula, operculum, anterior cingulate	4, 6, operculum	4, 7, 19, 23, 30, 32, operculum, anterior cingulate
2	7, 19, 30, 32, insula, operculum, anterior cingulate	4, 6, operculum	4, 7, 19, 30, 32, insula, operculum, anterior cingulate
3	7, 19, 23, 30, 32, insula, operculum, anterior cingulate	7, 19, 23, 30	7, 19, 23, 30, 32, operculum
4	4, 6, 30, 32, anterior cingulate	4, 6	4, 6, 30, 32, anterior cingulate
5	4, 7, 19, 23, 30, 32, anterior cingulate	4, 6, 23, 30, 32, anterior cingulate	4, 6, 30, 32
Subject	Single Trial		
	Lip pursing	Jaw clenching	Tongue rolling
1	6, 7, 19, 23, 30, 32, insula, operculum, anterior cingulate	6, 7, 19, 23, 30, 32, insula, operculum, anterior cingulate	4, 7, 19, 23, 30, 32, insula, operculum, anterior cingulate
2	7, 19, 30, 32, insula, operculum, anterior cingulate	4, 6, 7, 19, 30, 32, insula, operculum, anterior cingulate	4, 7, 19, 30, 32, insula, operculum, anterior cingulate
3	7, 19, 23, 30, 32, insula, operculum, anterior cingulate	7, 19, 23, 30, 32, insula, operculum, anterior cingulate	7, 19, 23, 30, 32, insula, operculum, anterior cingulate
4	4, 6, 30, 32, anterior cingulate	4, 6, 30, 32, anterior cingulate	4, 6, 30, 32, anterior cingulate
5	4, 7, 19, 23, 30, 32, anterior cingulate	4, 6, 23, 30, 32, anterior cingulate	4, 6, 30, 32, anterior cingulate

Numbers indicate Brodmann's areas.

the multifocal nature of the tested swallow-related motor tasks. The regions of clustered cortical activity for the swallow-related motor tasks were similar to the regions of clustered activity associated with volitional swallowing shown for the *group 2* data. The *group 3* data further elucidate the fact that both the swallow-related motor tasks and volitional swallowing are cortically multifocal and share similar regions of cortical activity. These regions of interest were determined a posteriori after analyzing the correlation data. The Brodmann areas in the definitions of these regions include all represented areas from all subjects. Comparison of the cortical activity volumes during swallowing and swallow-related motor tasks in four common regions among five subjects who performed a block trial of swallowing and the related motor tasks in the same setting (*group 3*) is shown in Fig. 3. As seen, total

volume of activity within each region for all tasks was similar. With two-way ANOVA, the volume of activity data was tested for variability between tasks and between cortical regions. Although there was no significant variability due to the different motor tasks in each region of interest, the motor/premotor region was characterized by greater cortical activity volume compared with the other regions of interest for all tasks ( $P \leq 0.05$ ). Comparison of maximum percent change in cortical fMRI signal intensity during rest and performance of the tasks showed that the percent increase in cortical activity during performance of all tasks averaged  $3.2 \pm 0.9\%$  for a single trial and  $7.1 \pm 1.6\%$  for block trials and did not show any statistical difference between various tasks or various regions.

## DISCUSSION

In this study, we compared the cerebral cortical representation of volitional swallowing and its related motor tasks. Study findings indicate that, similar to swallowing, volitional performance of swallow-related motor tasks such as jaw clenching, lip pursing, and tongue rolling is represented at various foci on the cortex. With swallowing, the findings of the present study corroborate previous reports in asymptomatic subjects without swallowing abnormalities (19, 20). These findings may also provide some explanation for the development of dysphagia in stroke and head injury patients (1, 2, 9, 13, 15, 16, 21, 25–29, 29, 31–33, 36) with involvement of various regions of the cortex. Previous studies of the cerebral cortical involvement in swallowing in humans fall into several categories. In the field of stroke and brain injury research, an indirect correlation has been made between the occurrence of swallowing disorders and the documented location of

Table 2. *Regions of activation in block- and single-trial studies of swallowing*

Subject	Block Trial
	Regions of Activation
1	7, 19, 23, 30, 32, insula, operculum, anterior cingulate
2	7, 19, 23, 30, 32, operculum, anterior cingulate
3	7, 19, 23, 32, insula, operculum, anterior cingulate
4	30, 32, insula, operculum, anterior cingulate
5	32, insula, operculum, anterior cingulate
Subject	Single Trial
	Regions of Activation
1	7, 19, 23, 30, 32, insula, operculum, anterior cingulate
2	7, 19, 23, 30, 32 operculum, anterior cingulate
3	7, 19, 23, 32, insula, operculum, anterior cingulate
4	30, 32, insula, operculum
5	32, insula, operculum, anterior cingulate

Numbers indicate Brodmann's areas.

Table 3. *Regions of cortical activity for all swallow-related motor tasks*

Subject	Swallowing	Lip Pursing	Jaw Clenching	Tongue Rolling
1	4, 6, 7, 19, 30, 32, insula, operculum	4, 6, 7, 19, 30, 32, insula, operculum	4, 6, 7, 19, 23, 30, 32, insula, operculum	4, 6, 7, 19, 23, 30, 32, insula
2	4, 6, 7, 19, 23, 30, 32, insula, operculum, anterior cingulate	4, 6, 7, 19, 23, 30, 32, insula, operculum, anterior cingulate	4, 6, 7, 19, 23, 30, 32, insula, operculum	4, 6, 7, 19, 23, 30, 32, insula, operculum, anterior cingulate
3	4, 6, 7, 19, 23, 32, insula, operculum, anterior cingulate	4, 6, 7, 19, 23, 30, 32, insula, operculum, anterior cingulate	23, 30, 32, insula	4, 6, 30, insula, operculum, anterior cingulate
4	4, 6, 23, 30, 32, insula, operculum, anterior cingulate	30, 32, anterior cingulate	30, 32	4, 6, operculum, anterior cingulate
5	4, 6, 7, 19, 23, 30, 32, insula, operculum, anterior cingulate	4, 6, 7, 19, 23, 30, 32, insula, operculum, anterior cingulate	7, 19, 23, 30, 32	4, 6, 30, 32, insula, operculum, anterior cingulate

Numbers indicate Brodmann's areas.

cortical insult. These studies primarily focus on the relationship between the cerebral vascular location of stroke or injury and the associated deglutitive deficits. Together, these studies report both anterior and posterior cortical insult as well as brain stem stroke, in isolation or combination, as a causative factor to dysphagic symptoms such as aspiration (2, 15, 28), diminished deglutitive hyolaryngeal mechanics (28), poor timing and coordination of deglutitive events (15, 16, 32, 33), and sensory discrimination (36). These findings support the idea of multiple cortical regional involvement in volitional swallowing.

The effect of direct stimulation of the cortex on some deglutitive muscles has been studied using transcranial magnetic stimulation. By magnetically stimulating specific cortical areas and simultaneously monitoring electromyographic activity in some of the deglutitive muscles in humans (16, 18), specific areas of the motor/premotor cortex were found to be related to the activity of the deglutitive muscles. These transcranial magnetic stimulation techniques are limited to mapping of the outer cortical surfaces; however, the influence of deeper and more caudal centers such as the operculum and the insula has been hypothesized (16, 18). The transcranial magnetic stimulation technique has been applied to the evaluation of swallow recovery after stroke (17). In these studies, recovery of swallowing ability was associated with contralateral hemispheric reorganization of the sites associated with the swallow-related muscles. Interestingly, the site of stroke was not found to be directly related to the premotor or motor regions identified as being affiliated with the tested deglutitive muscles but rather to regions remote from the motor area such as the parietal and temporal regions and the brain stem. These studies also indirectly support the multifocal nature of cerebral cortical involvement in volitional swallowing.

More recently, the single-trial fMRI technique has been applied to swallowing (5, 6, 8, 19), showing the efficacy of the single-trial technique for studying motor tasks inherently associated with brief motion of the head and neck muscles such as swallowing. These studies have shown similar regions of activation to those reported in the present work; however, the signal

response in one of the studies showed greater latency and signal increase duration than those reported in the present study (19). One explanation for this discrepancy is that the subjects in the cited study swallowed 5-ml water boluses, whereas subjects in the present study swallowed their ambient saliva.

The results of the present study indicate that cortical activation was associated with swallowing in four general areas: the anterior cingulate, the motor/premotor cortex, the insula, and the occipital/parietal region, corresponding to Brodmann's areas 7, 19, and 31. These findings corroborate earlier work from our lab (5, 6) and others using fMRI (19) as well as studies of deglutitive cortical processes using other analytical modalities and clinical methods (1, 2, 9, 13, 15, 16, 18, 21, 25–29, 31–33, 36).

The anterior cingulate is a recognized center for the processing of painful stimulus and attention to volitional actions as well as the processing of the affective components of emotion (17–20, 23). Changes in cerebral cortical hemodynamics have been shown for this region during chemical and mechanical stimulation of the esophagus (23). Our findings support the notion that activation of this region during volitional swallowing may reflect the attention component of the swallow task. Study findings also show this region to be involved in swallow-related motor tasks, supporting the notion of involvement of the anterior cingulate as a nonspecific site for attention associated with other motor tasks in addition to deglutition.

Our study corroborates previous reports of cortical activity in the motor/premotor areas during swallowing. This area represents a controlling region for oropharyngeal deglutitive muscle activity. Inferences with regard to the somatotopic mapping of the motor region specific to swallowing were not possible given the relatively large voxel sizes used in the present study; however, study findings indicate that swallowing involves both hemispheres, with larger and more intense activity present in the right hemisphere. It is interesting to note that the motor/premotor areas have greater volume recruitment in the right hemisphere in




Fig. 2. Regions of cortical signal change. Presence (+) or absence (-) of a signal change within designated anatomic locations that meet or exceed correlation criteria and in which a "cluster" criteria has also been met, a cluster being as set of at least 3 contiguous, correlated voxels. Note that *subject 4* in *groups 1* and *2* was left handed. O, occipital cluster; I, insular cluster; A, anterior cingulate cluster; M, motor/premotor cluster. \*Greater %increase and ‡greater volume for right vs. left hemisphere.

the right-handed subjects tested in our study. The lone left-handed subject, however, showed greater volume in the left hemisphere motor/premotor region.

Cortical insult of the insula (2, 13, 29), operculum (2, 25, 32), premotor and motor areas (32), and the cingulate gyrus (26) has been associated with documented swallow-

ing deficits or abnormal deglutitive muscle activity. Our study findings have shown insular involvement in swallowing to be bilateral but hemispherically asymmetric in some subjects. These findings substantiate previous reports concerning the development of dysphagia in subjects with isolated right anterior insular stroke (16).

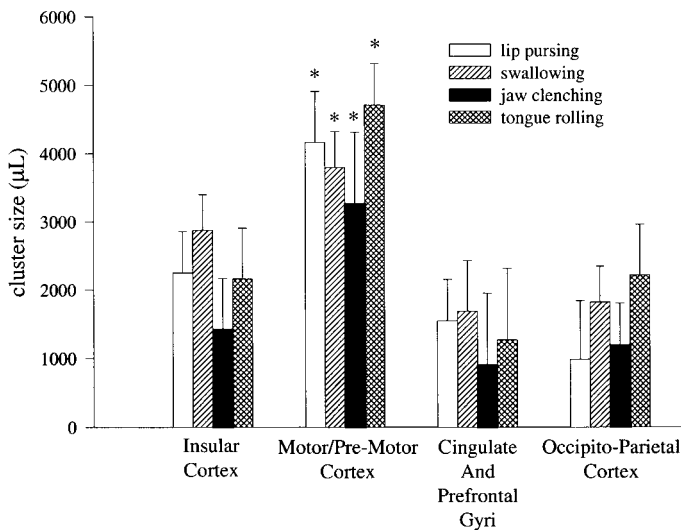


Fig. 3. Comparison of volume of regional cortical fMRI activity during swallowing, lip pursing, jaw clenching, and tongue rolling. The occipitoparietal regions include Brodmann areas 7, 19, 23, 26, and 30. As seen, within each region the volume of fMRI activity was similar for all tasks. However, between-region comparison showed a significantly larger volume of fMRI activity in the motor/premotor region compared with insular, anterior cingulate, and occipitoparietal regions ( $*P < 0.05$ ).

Activation of the occipitoparietal regions during swallowing has been previously reported (19, 20) and is corroborated in our study. This region has been cited as a region of activity during mechanical and chemical stimulation of the esophagus (23) as well as during the sensation of swallow urge (22). The occipitoparietal region is networked to the limbic and prefrontal/anterior cingulate regions that we have also shown to be activated during swallowing and swallow-related motor tasks. The occipitoparietal regions are thought to be a general hub for processing and integrating sensory input with motor output as well as association of visual and auditory cues to sensory/motor response (10). Furthermore, the superior parietal lobe (Brodmann area 7) is part of the posterior attention system and is involved in selecting one stimulus over another and creating plans of action regarding that stimulus. The interconnections with the frontal/anterior cingulate cortex are crucial in this regard (10). Thus two possible explanations for activation of the occipitoparietal region during our experiment exist. One explanation may be that the region is activated by the cue to perform a motor task rather than by the motor task itself. Another explanation for activity in the occipitoparietal region is that the measured activity is directly attributable to the motor task stimulus. The former explanation regarding the cue to perform a motor task seems less likely since pilot data from our lab and others (19) on ad lib swallowing has shown the occipitoparietal region to be active during volitional swallowing in the absence of any external cueing. Furthermore, no cortical activity is seen during fMRI scans when the cue for a motor task is given but no motor task is performed.

Findings of the present study also show swallow-related motor tasks to be bilaterally represented with-

out conclusive evidence of hemispheric propensity in terms of cluster volume or percent increase of magnetic field from baseline.  $\chi$ -Squared analysis of the incidence of greater hemispheric activity volume shows no clear picture of hemispheric dominance. For jaw clenching, the right insula and right motor/premotor regions showed greater volumes of activity in 83 and 78% of subjects, respectively; however, no hemispheric dominance was shown for the incidence of activity in the occipitoparietal and anterior cingulate hemispheres during jaw clenching. Lip pursing was bilaterally represented for volume of activity in all cortical regions. Tongue rolling showed a high incidence of right hemispheric motor (64%) and anterior cingulate (75%) activity, with no clear volume dominance for insular and occipitoparietal regions. Part of the reason for these inconclusive findings may be the large size of the voxels used in this study. Future studies using a smaller voxel size focused on individual regions are needed to address these issues conclusively. This is in contrast to volitional swallowing, which shows a marked dominance of right hemispheric cortical activity in terms of both volume and intensity of the activated regions. However, the regions of activity, volume of activated voxels, and increases in signal intensity were found to be similar between volitional swallowing and swallow-related motor tasks, indicating similar cortical processing. Since the viscerotropic representation of swallow-related motor tasks is known to encompass the motor cortex, this similarity afforded by the activation of other areas such as prefrontal, cingulate, and insular cortex may represent the influence of volition and intent shared between performance of these tasks.

As stated above, however, there may be differences between cortical activity during swallow and its related motor tasks that have escaped detection because of the voxel size used in this study. The possibility of subtle regional cortical differences between swallowing and swallow-related motor tasks needs to be explored using a smaller voxel size.

As shown previously (5, 6), the single-trial technique eliminates much of the motion-related artifact associated with swallowing and swallow-related motor tasks such as jaw clenching, tongue rolling, and lip pursing. The present study has further shown that averaging the response to the block-trial paradigm yields cortical activity maps that are very similar to that of the single-trial paradigm, suggesting that this technique may be used reliably, provided that the response data from several block trials are combined.

In conclusion, both swallow-related motor tasks and volitional swallowing are represented cortically in discrete and multifocal regions. Cortical representation of swallow-related motor tasks such as tongue movement, lip pursing, jaw clenching, and volitional swallowing are similar, suggesting that cerebral cortical regions involved in swallowing may not be specific to deglutition. The multifocal nature of deglutitive cortical topography of volitional swallowing and its related motor events may explain the common occurrence of

acute or chronic swallow deficits in stroke patients following ischemic insult involving various cerebral regions.

## REFERENCES

1. **Aguilar NV, Olson ML, and Shedd DP.** Rehabilitation of deglutitive problems in patients with head and neck cancer. *Am J Surg* 138: 501–507, 1979.
2. **Alberts MJ, Horner J, Gray L, and Brazer SR.** Aspiration after stroke: lesion analysis by brain MRI. *Dysphagia* 7: 170–173, 1992.
3. **Bandettini PA, Jesmanowicz A, Wong EC, and Hyde J.** Processing strategies for time course data sets in functional MRI of the human brain. *Magn Reson Med* 30: 161–173, 1993.
4. **Bandettini PA, Wong EC, Hinks RS, Tikofsky RS, and Hyde JS.** Time course EPI of human brain function during task activation. *Magn Reson Med* 25: 390–397, 1992.
5. **Birn RM, Bandettini PA, Cox RW, and Shaker R.** Event-related fMRI of tasks involving brief motion. *Hum Brain Mapp* 7: 106–114, 1999.
6. **Birn RM, Bandettini PA, Cox RW, and Shaker R.** Improved technique for study of brain activity during swallowing by functional magnetic resonance imaging (fMRI) (Abstract). *Gastroenterology* 114: A720, 1998.
7. **Biswal B, Yetkin FZ, Hyde J, and Haughton VM.** Functional connectivity of the auditory cortex studied with fMRI. *2nd Internat Conf Funct Mapp Hum Brain*, 1996, p. S421.
8. **Buckner RL, Bandettini PA, O'Craven KM, Savoy RL, Petersen SE, Raichle ME, and Rosen BR.** Detection of cortical activation during averaged single trials of a cognitive task using functional magnetic resonance imaging. *Proc Natl Acad Sci USA* 93:14302–14303, 1996.
9. **Cherney LR and Halper AS.** Swallowing problems in adults with traumatic brain injury. *Semin Neurol* 16: 349–353, 1996.
10. **Clark DL and Boutros NN.** *The Brain and Behavior: an Introduction to Behavioral Neuroanatomy*. Malden, MA: Blackwell Science, 1999.
11. **Cox RW.** AFNI: software for analysis and visualization of functional magnetic resonance neuroimages. *Comput Biomed Res* 29: 162–173, 1996.
12. **Crosson B, Rao SM, Woodley SJ, Rosen AC, Hammeke TA, Bobholz JA, Cunningham JM, Fuller SA, Binder JR, and Cox RW.** Mapping of semantic vs. phonologic vs. orthographic verbal working memory in normal adults with fMRI. *Second International Conference on Functional Mapping of the Human Brain* 3: S538, 1996.
13. **Detoleto J, Icovinno J, and Haddad H.** Swallowing difficulties and early CNS injury. *Brain Inj* 8: 607–611, 1994.
14. **Deyoe EA, Bandettini P, Neitz J, Miller D, and Winans P.** fMRI of the human brain. *J Neurosci Methods* 54: 171–187, 1994.
15. **Field LH and Weiss CJ.** Dysphagia with head injury. *Brain Inj* 3: 19–26, 1989.
16. **Hamdy S, Aziz Q, Rothwell JC, Crone R, Hughes DG, Tallis RC, and Thompson DG.** Explaining oropharyngeal dysphagia after unilateral stroke. *Lancet* 350: 686–692, 1997.
17. **Hamdy S, Aziz Q, Rothwell JC, Power M, Singh KD, Nicholson DA, Tallis RC, and Thompson DG.** Recovery of swallowing after dysphagic stroke relates to functional reorganization in the motor cortex. *Gastroenterology* 115: 1104–1112, 1998.
18. **Hamdy S, Aziz Q, Rothwell JC, Singh KD, Barlow J, Hughes DG, Tallis RC, and Thompson DG.** The cortical topography of human swallowing musculature in health and disease. *Nat Med* 2: 1217–1224, 1996.
19. **Hamdy S, Mikulis DJ, Crawley A, Xue S, Lau H, Henry S, and Diamant NE.** Cortical activation during volitional swallowing: an event related fMRI study. *Am J Physiol Gastrointest Liver Physiol* 277: G219–G225, 1999.
20. **Hamdy S, Rothwell JC, Brooks DJ, Bailey D, Aziz Q, and Thompson DG.** Identification of the cerebral loci processing human swallowing with H<sub>2</sub><sup>15</sup>O PET activation. *J Neurophysiol* 81: 1917–1926, 1999.
21. **Horner J, Buoyer FG, Alberts MJ, and Helms MJ.** Dysphagia following brain stem stroke. Clinical correlates and outcome. *Arch Neurol* 48: 1170–1173, 1991.
22. **Kern MK, Arndorfer R, Hyde JS, and Shaker R.** Cortical representation of the swallow urge in healthy young volunteers (Abstract). *Neurogastroenterol Motil* 11: 269, 1999.
23. **Kern MK, Birn RJ, Jaradeh S, Jesmanowicz A, Cox RW, Hyde JS, and Shaker R.** Identification and characterization of cerebral cortical response to esophageal acid exposure and distension. *Gastroenterology* 115: 1353–1362, 1998.
24. **Kwong KK, Belliveau JW, Chesler DA, Goldberg IE, Weisskoff RM, Poncelet BP, Kennedy DN, Hoppel BE, Cohen MS, Turner R, Cheng H, Brady TH, and Rosen BR.** Dynamic magnetic resonance imaging of human brain activity during primary sensory stimulation. *Proc Natl Acad Sci USA* 89: 5675–5679, 1992.
25. **Lampl Y, Steinmetz A, Gilad R, Eshel Y, Chamovitz D, and Sarova-Pinhas I.** Anterior operculum syndrome localized by SPECT. *J Nucl Med* 38: 1122–1124, 1997.
26. **Leckman JF, deLotbiniere AJ, Marek K, Gracco C, Seahill L, and Cohen DJ.** Severe disturbances in speech, swallowing and gait following stereotactic infrathalamic lesions in Gilles de la Tourette's syndrome. *Neurology* 43: 890–894, 1993.
27. **Levine R, Robbins J, and Maser A.** Periventricular white matter changes and oropharyngeal swallowing in normal individuals. *Dysphagia* 7: 142–147, 1992.
28. **Logemann JA, Shanahan T, Rademaker AW, Kahrilas PJ, Lazar R, and Halper A.** Oropharyngeal swallowing after stroke in the left basal ganglion/internal capsule. *Dysphagia* 8: 230–234, 1993.
29. **Martin RE and Sessle BJ.** The role of the cerebral cortex in swallowing. *Dysphagia* 8: 194–202, 1993.
30. **Menon RS, Ogawa S, Kim S, Ellermann JM, Merkle H, Tank DW, and Ugurbil K.** Functional brain mapping using magnetic resonance imaging. *Invest Radiol* 27: S47–S53, 1992.
31. **Park CL, O'Neill PA, and Martin DF.** A pilot study of oral electrical stimulation on swallow function following stroke: an innovative technique. *Dysphagia* 12: 161–166, 1997.
32. **Robbins J and Levine RL.** Swallowing after unilateral stroke of the cerebral cortex: preliminary experience. *Dysphagia* 3: 11–17, 1988.
33. **Robbins J, Levine RL, Maser A, Rosenbek JC, and Kempster GB.** Swallowing after stroke of the cerebral cortex. *Arch Phys Med Rehabil* 74: 1295–1300, 1993.
34. **Stein EA, Pankiewicz J, Harsch HH, Cho JK, Fuller SA, Hoffmann RG, Hawkins M, Rao SM, Bandettini PA, and Bloom AS.** Nicotine-induced limbic cortical activation in the human brain: a functional MRI study. *Am J Psych* 155: 1009–1015, 1998.
35. **Talairach J, Tournoux P, Musolino A, and Missir O.** Stereotaxic exploration in frontal epilepsy. *Adv Neurol* 57: 651–688, 1992.
36. **Traversa R, Cicinelli P, Bassi A, Rossini PM, and Bernardi G.** Mapping of motor cortical reorganization after stroke. *Stroke* 28: 110–117, 1997.